

Spring  
2010 Issue

# Technically Speaking

## **Special Interest Articles:**

- Message from MSRT President

## New Editor of Technically Speaking

In the summer of 2009 Dawn M. Dickinson RT(R) (M) (CT) retired as editor of Technically Speaking to pursue her career goals by enrolling in the RA program at Wayne State University (congratulations Dawn). Here I am, in the winter of 2010 to introduce myself as the new editor of Technically Speaking.

I am relatively new to the field of Radiography. I graduated from Washtenaw Community College in the summer of 2009 with an Associate's Degree in radiography. Radiography is a second career for me so I am approaching this opportunity as a "mature" individual starting a second career at the age of 50.

In 1986 I obtained a degree from the University of Michigan, in Ann Arbor and have worked in auditory research since that time. For 15 years I worked with primates doing operant conditioning positive reinforcement training and for the last 8 years I have worked in a Human Psychophysical Laboratory doing research with adults who have cochlear implants. For the past 4 years the lack of federal grant money enticed me to look seriously at my career and future in research. Realizing the future was bleak, I set out to find a field, which I could count on to keep me employed and vacationing. My investigations revealed that the field of radiography was growing and had many modalities to choose from. So, my journey thru the educational process over the past 2 years has brought me to this point: Certified Radiological Technologist just starting in the field, new editor of an online publication for radiologic technologists and a recently certified scuba diver.

This is an exciting time for the MSRT website. The publication has gone through a very successful upgrade over the past year. As I look back thru the previous issues I am impressed with the current look and design.

In 2008 Rex Miller had some great suggestions for the publication such as working on tracking membership CE credits, on-line CE credits, improved communication, greater networking and MSRT stores.

I have been thinking about what I would like to see featured in Technically Speaking; websites that are exemplary in helping with anything related to radiography, features on co-workers who we admire, positioning tips and interviews with radiologists and guidelines they might have for radiographers.

I am interested in hearing what you, as the readers would like to see in the publication. Please email me with suggestions, articles or anything else that might be of interest to you.

Catherine Thompson (RT) R  
Editor  
cathyt@umich.edu

## Message from the president

Good Day and hope all is well for you in the New Year!

It was good to see you many of you at the annual Meeting in October in our new location-the Double Tree Hotel (Bay City-Waterfront). The rain did not stifle any of the enthusiasm nor distract from the beautiful new facility. The neighborhood has several good places to eat and many of us enjoyed a fun presentation at the planetarium.

The three days of educational programs and nighttime activities were great! We again need to thank Brian Pickford, Tim Wescott and the rest of the 2009 Annual Meeting committee. Their dedication to our society is truly appreciated. There was a huge student participation in Wednesday night's Student Bee. Thank you to Paul Keroson for updating the format. The competition was tough and exciting.

We are pleased announce that we will return to the Double Tree Hotel, Bay City for the 2010 Annual Meeting. The dates are September 15-17. The golf outing is scheduled for Tuesday, September 14<sup>th</sup>. Make your plans now to attend.

The Mid America Conference is March 19 and 20<sup>th</sup> at the Holiday Inn Flint Gateway Centre. This conference also has great attendance and loyal attendees. Watch for updates on our website [MSRT.org](http://MSRT.org).

The MSRT has an opening for the Registrar position. Bill Muller has been a great asset to our organization and will be missed. Bill has agreed to help the next Registrar through the 2010 Annual Meeting. If you are interested please send a cover letter and resume to me: [president@msrt.org](mailto:president@msrt.org)

We will also be seeking an MSRT member to fill the Treasurer and other Officer positions. PLEASE consider joining the Board as an officer or as a committee chair! Officer nominations need to be submitted to Laurie Williams through my email ([president@msrt.org](mailto:president@msrt.org)). Members interested in Committees should contact President elect Joe Prevo ([preselect@msrt.org](mailto:preselect@msrt.org)).

These are wonderful opportunities to interact with many technologists in a variety of specialties who care about the students and technologists in this state and country and the safety of all patients.

The Planning and Research committee has worked to improve the efficiency of our website including conference information, registration and member portal. I wish to thank Rex Miller, Chris Boyce and Todd Williams for all their tirelessly efforts. Our goal is CE tracking for MSRT members for their attendance at MSRT conferences.

I encourage all MSRT members to use the dropdown "Members" on our website and confirm your email address. This will be a vital component for MSRT member access and this is the most error free way to connect you to your CE records. Your email address will be used exclusively for your access to obtain your CE records. Your address will not be used for spam or sold for others to use!

I look forward to meeting and working with you this year!!

Deborah Bickerstaff RT(R)(M)  
President



---

**Mid-America  
Conference**

**March 19-20, 2010**

---

**MSRT**

**Annual Meeting**

**Sept. 15-17, 2010**

## Technologist of the year award

### MSRT Technologist of the year nominations

The Michigan Society of Radiologic Technologists established the "Technologist of the Year Award" in 1968. This award has always been considered to be one of the highest honors given to a technologist who has proven to be an outstanding example of our profession and has aided in the advancement of our society.

As Second Vice-President of the MSRT, it is my duty and privilege to ask our Membership to nominate those individuals qualified as Candidates for this prestigious award. Any member of the MSRT may submit their recommendations for Candidates. Please refer to the following guidelines when considering your nomination. You may forward your completed form directly to me by July 1, 2010.

#### **MSRT "Technologist of the Year" Guidelines**

Any MSRT Member may submit a nomination. Requirements for each nominee will be:

- Active Member in good standing

The President, President Elect, Board Chairperson, and Second Vice-President are not eligible.

Each nominee will be judged on:

- Personality
- Professional attitude
- Achievements in MSRT and other professional societies
- Achievements and accomplishments in continuing education
- Awards received
- Community activities
- Letters of recommendation

Please note: Letters of recommendation should include information pertaining to the following: quality of work, abilities as a technologist, professionalism, rapport with patients, students and fellow workers where applicable.

Please return forms to:

Bonita M. Pawloski  
Second Vice-President  
Michigan Society of Radiologic Technologists  
283 Kara Ave SW  
Walker, MI 49534



## MSRT Scientific Display Honorees

Michigan Society of Radiologic Technologists  
2009 Annual Meeting

### Technologist/Graduate Technologist

First Place: Bruce Bailey, *Radiology Myth's and Legends*

Second Place: Robert Young, *Monitor Generated Artifacts*

### Student Technologists

First Place: Justyna Schab *Accelerated Partial Breast Irradiation*

Second Place: Amelia Gritter, *Instrumentation of PET/CT*

(Tie) Third Place: Julie Helder, *Safer CT Scanning for Pediatric Patients*

(Tie) Third Place: Nancy Nguyen, *Brachytherapy*

### Honorable Mention:

Rachel Powell, *Multi Leaf Collimation vs. Blocks*

Sarah Arena, *The Doppler Affect*

The MSRT wishes to thank all those who took part in the Scientific Display Competition.

---

## 2009 Student MSRT essay winners

Congratulations to the winning essay writers. The competition was tough and the essays were all well written. In *Technically Speaking* we will be featuring the top 3 essays (3<sup>rd</sup> place was a tie). Here is the top student essay of 2009.



A Comprehensive Analysis of Post-Mastectomy Reconstruction  
and Radiation Therapy Treatments to a Temporary Tissue Expander

Aria Kasputis  
Grand Valley State University  
Radiation Therapy Program  
Submitted on 13 July, 2009

A Comprehensive Analysis of Post-Mastectomy Reconstruction  
and Radiation Therapy Treatments to a Temporary Tissue Expander

When a woman is diagnosed with breast cancer, her world quickly turns upside-down, which is a difficult position to be in when life-affecting decisions must be made. Treatment options as well as reconstructive procedures are quickly thrown at the patient, and while they are still grappling with their diagnosis and what it means to them and their family, they are forced to make a decision. For women with advanced disease, mastectomy is typically the surgery of choice, and the option of breast reconstruction is always presented, followed by other possible treatments that may be required. There are many issues surrounding post-mastectomy reconstruction and radiation therapy to temporary tissue expanders, and unfortunately, a clear and concise guide explaining the many sides of these issues does not get stuffed into the patient's new information folder – their new life guide. Extensive research compiles the following comprehensive analysis of issues and controversies surrounding post-mastectomy reconstruction and radiation therapy treatments to a temporary tissue expander.

Breast reconstruction with a tissue expander can be performed during the mastectomy surgery once the breast tissue has been removed (immediate reconstruction) or as a separate surgery after the mastectomy (delayed reconstruction). Many sources cite different benefits and problems with both immediate and delayed breast reconstruction, as well as the use of radiation therapy with a tissue expander in place, all of which will be discussed within this analysis. One benefit of immediate breast reconstruction discussed in many texts is the psychological benefit to the patient. Al-Ghazal has conducted two studies in regards to the psychological benefit of breast reconstruction. The first states that patients that undergo immediate reconstruction post-mastectomy suffer less distress and psychosocial morbidity than patients that underwent

delayed reconstruction (Al-Ghazal, Blamey, Fallowfield & Sully, 2000). The second study followed 577 patients after breast surgery: 254 that underwent a conservative lumpectomy surgery, 202 underwent mastectomy, and 121 underwent mastectomy along with breast reconstruction. Among all of the patients that had a mastectomy, those that underwent immediate reconstruction had a much lower incidence of problems such as depression and anxiety than those who did not have the reconstruction (Al-Ghazal, Blamey & Fallowfield, 2000). In a similar fashion, Druss et al. (1984) and Andradas-Aragones et al. (2008) found that patients that underwent immediate breast reconstruction had less psychological issues than those who did not receive the reconstruction, who proved to experience more emotional issues.

Another issue that must be considered is satisfactory cosmesis of the reconstruction. Hudis et al. (2006) state that negative cosmetic outcomes are widely reported when radiation therapy is delivered to the reconstructed breast. Donegan and Spratt (2002) add that those who receive radiation therapy treatments to a tissue expander are at a higher risk of infection, capsular contracture, and inadequate expansion of the tissue expander, all leading to suboptimal cosmetic outcomes. Bosworth et al. (2008) conducted a study of 92 patients, 69 of which received radiation therapy to a tissue expander. Of these patients, only 51% of the patients reported acceptable cosmetic outcomes, leaving 49% of the women unhappy with how the reconstruction turned out in the end. Considering this, one could argue that although immediate reconstruction provides better psychological outcomes immediately after the mastectomy surgery, approximately one-half of these patients that require post-mastectomy radiation therapy

will be unhappy with the outcome of the reconstruction, which may cause psychosocial and emotional problems at that time.

Radiation therapy treatments have the ability to improve long-term survival rates by reducing locoregional recurrence; these treatments aid in saving the patient's life, and it is argued that the presence of a tissue expander may decrease the effectiveness of the treatments (Buchholz, McNeese, Perkins, & Strom, 2002). In fact, Buchholz et al. (2002) report that 24% of patients with lymph node-positive disease that did not receive radiation treatments had locoregional failure, compared to only 9% of patients that received post-mastectomy radiation therapy. During immediate breast reconstruction, the tissue expander is inserted prior to receiving the pathology report from the tissue collected during the mastectomy, which decides whether the patient should undergo radiation therapy treatments (Babiera et al., 2004). This suggests that immediate reconstruction should not be performed due to the possible complications of radiation therapy to the tissue expander (Hudis, Norton, and Winchester, 2006, and Kronowitz and Robb, 2004).

It is argued that issues that affect the cosmesis of reconstructed breasts after radiation therapy treatments are caused by complications due to the interaction of radiation with the tissue expander, which may cause more lethal damage than decreased cosmetic outcome. Morgan and Thompson (2005) investigated the effects of radiation therapy treatments on the MAGNA-SITE™ tissue expander, focusing on backscatter and side scatter. Using a water phantom and diode detectors, the amount of dose received to areas adjacent to the magnet within the tissue expander was studied, including both side- and back-scatter. While it was shown that the effects of side scatter increased the dose by

2.75% and the effects of backscatter increased the dose by 4%, it is believed that the scattered electrons secondary to the interaction of the beam with the metallic tissue expander are absorbed by parts of the tissue expander, therefore most likely not increasing the dose to the breast tissue. A reduction in dose was reported in the area near the center of the tissue expander, where the thickest section of metal was located when the beam irradiated the tissue expander from both parallel and perpendicular directions. This may account for under-dosing certain regions by 30%, although it is more realistic that part of the planning target volume may be under-dosed by 10%. It is noted that both diseased tissue and parts of the tissue expander may receive less dose than intended, which inadvertently affects the treatment of the disease, possibly increasing the local recurrence rate as well as decreasing the patient's survival. This study also reported that the high CT number of the tissue expander affects image quality during scanning, which caused unacceptable images for treatment planning. The suggestion for correction included disabling the CT-based density correction and assigning a bulk correction to the lung. Ballangrud et al. (2006) concur that irradiating the MAGNA-SITE™ tissue expander decreases transmission of the beam to regions near the port, but that the volume of actual tissue affected is small. They recommend treating a permanent implant, but if the tissue expander is being irradiated, then use of a 15 MV photon beam with bolus may help the dosimetric outcome. On the contrary, Cederna et al. (2004) performed a similar study as that of Morgan and Thompson's and Ballangrud's, using thermoluminescent dosimetry detectors to explore whether the metallic port of the tissue expander is the cause of the 50% complication rate of irradiating tissue expanders. The study did not show any significant scatter, and excess dose was absorbed by the casing of the port,

suggesting that the dosimetry in patients with a tissue expander does not contribute to the high complication rate.

Aside from the argument of scatter and under-dosing due to the tissue expander, another reason that immediate reconstruction is controversial when related to post-mastectomy radiation therapy treatments is the quality of the dosimetry within the treatment plan that is provided. Buchholz et al. (2002) discussed the sequencing of post-mastectomy radiation therapy, and concluded through research that the field design is greatly affected when tissue expanders are present. Reconstruction surgeries may distort the anatomy, which leads to the production of a treatment plan that includes more dose to the lungs and heart than typically necessary due to the curvatures and slopes of the chest wall and breast mound secondary to the tissue expander. Two problems occur due to the presence of the tissue expander: the chest wall becomes non-uniform in thickness, which delivers an inhomogeneous dose to the internal mammary nodes, and the slope of the expanded breast mound causes certain areas within the junction between the two tangent chest wall fields to be under-dosed (slide 1). Image “B” shows a breast with a tissue expander being treated with tangential photon fields to the chest wall and an electron field treating the internal mammary lymph nodes abutting the photon fields. Due to the slope of the breast mound, the match of the abutting photon fields with the electron field is not precise, causing the under-dosed area between the electron field and tangential photon fields. Other studies have been conducted examining the dosimetry within the treatment plan for patients with tissue expanders. Arzu et al. (2005) reviewed 18 radiation therapy plans of patients with tissue expanders and looked at four factors: chest wall coverage, coverage of the internal mammary lymph node chain, avoidance of heart

exposure, and minimal lung exposure. Of the 18 plans, 12 plans compromised chest wall coverage, nine plans did not cover any of the internal mammary chain, and only four plans treated the patient optimally. This study showed that of the small sample size, only 22% of the patients received the optimal treatment that patients without tissue expanders receive. Buchholz et al. (2006) studied the same four factors of treatment as they reviewed 112 treatment plans of patients with tissue expanders and compared these plans to patients without tissue expanders. Of the 112 treatment plans, 52% of the plans were compromised, compared to 7% compromised plans in the non-tissue expander control group. Of the 52% of patients that received suboptimal treatment due to the presence of the tissue expander, 33% of the patients had moderately-compromised plans, and 19% were severely compromised. The study concluded that most of the compromised plans were those that were treating the left breast, and that the possibility of post-mastectomy radiation therapy should be strongly considered when deciding between immediate and delayed breast reconstruction. Ashton, Goldson, Nibhanupudy, Shankar, and Sridhar (2003) document that the presence of a tissue expander during radiation treatments may put the prosthesis under mechanical strain, causing it to shift and change shape, which in turn may move the expander into or out of the treatment field, causing changes in dosimetry. This has the capability of causing inaccurate delivery of radiation therapy treatments. Experiments with a phantom and hypothetical situations such as the expander moving 1cm out of the treatment field, dimpling of the prosthesis, and change in the size and/or shape of the tissue expander all brought about unacceptable changes to the treatment plan, causing variations in the plan greater than 10% and resulting in significant over-dosing or under-dosing as well as decreased tumor control.

The clinical advantage of delivering an electron “boost” to the scar of the breast area from the mastectomy is well documented in literature with an overwhelming consensus that the boost decreases locoregional recurrence, which in turn also increases survival rates. Hudis et al. (2006) explain that the operative flaps typically receive 10 to 16 Gy of low-energy electrons, citing that the EORTC found that a 16 Gy boost reduced local recurrence from 6.8% to 4.3%, and a study by The Lyon Group concurred that a 10 Gy boost reduced local recurrence from 4.5% to 3.6%. Benda, Feigenberg, Mendenhall, and Morris (2003) studied the causes of treatment failure and factors causing locoregional recurrence in 323 patients receiving radiation therapy treatments. Findings suggested that patients with positive margins benefited from an electron boost to 6500 cGy. However, radiation oncologists shy away from delivering this evidently beneficial electron scar boosts to patients with tissue expanders in place, and the reason for this is not well studied or documented. Radiation Oncologist Dr. C. Michael Wilkinson (personal communication, July 9, 2009) explains that an electron boost is typically not delivered with patients that have a tissue expander in place because there is a very high possibility of geographical miss; the oncologist and dosimetrist cannot figure out where the tumor bed is located because the tissue moves out of place during expansion. More specifically, when the expander is placed and expanded, the cells within the area of the breast mound are shifting, and any remaining diseased cells may move throughout the breast area, and there is no way to pinpoint where the diseased cells are. There is no justified reason to deliver the incisional boost, and the patients are losing what European trials have shown to be a 2-3% improvement of disease-free survival due to the boost, as stated above.

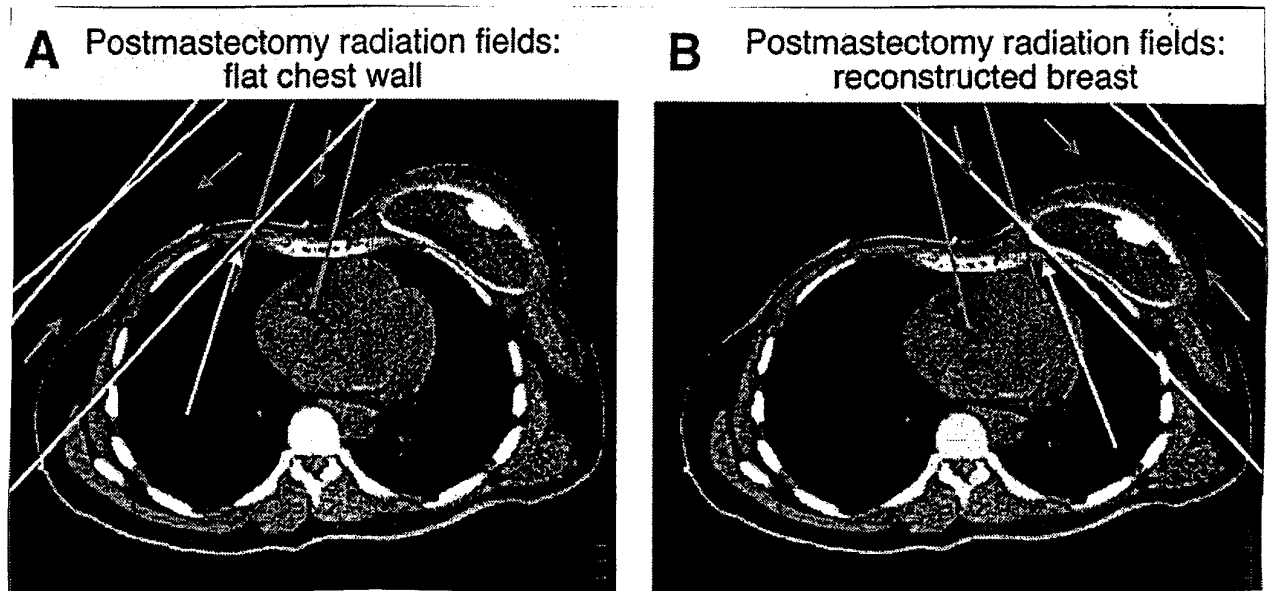
While the above information suggests that delayed reconstruction in patients that require post-mastectomy radiation therapy would provide for a better treatment plan, the quality and cosmetic outcome of delayed reconstruction may not be as high after radiation treatments. Mosiello and Shons (2001) explain that radiation treatments damage skin by impairing replication. Toward the end of the treatments and for a time period after treatments are completed, the skin above the chest wall where the mastectomy took place is red, inflamed, and swollen, which is followed by fibrosis, skin contraction, and loss of skin elasticity. This severely complicates delayed breast reconstruction, because it is proven to be difficult to insert an implant or tissue expander after radiation treatments due to the effects of the radiation on the skin. Ashton et al. (2003) agree that augmentation post-radiation treatments have higher complication rates and lower cosmetic ratings, and Buchholz et al. (2002) add that the lack of elasticity due to radiation treatments significantly compromises the success of delayed reconstruction.

Many factors contribute to the controversies discussed above, and a few texts have surfaced offering solutions to some of the issues surrounding post-mastectomy reconstruction and radiation therapy to tissue expanders. Hudis et al. (2006) state that the M.D. Anderson Cancer Center has begun utilizing delayed-immediate reconstruction, during which the tissue expander is placed during the mastectomy, and once the pathology is reviewed, decisions of delayed versus immediate reconstruction are made. If the patient does not need post-mastectomy radiation treatments, the reconstruction process begins immediately. However, if the patient requires radiation treatments, the expander is deflated to reduce issues with radiation delivery and to accommodate a better treatment plan. Once the radiation treatments are completed, the expander is re-inflated,

and delayed reconstruction takes place. Hudis et al. realize that this is a relatively new approach, and that the outcome of delayed-immediate reconstruction must be studied, as the cosmesis and long-term effects are not yet known. Asthon et al. (2003) suggest monitoring the patient throughout the course of treatments to assure that the tissue expander is not causing any issues. The study followed one patient, utilizing a CT scanner to verify the position of the tissue expander and to detect any changes to the expander or surrounding structures. In the case of this patient, no changes were found during the treatments. The study explains that the additional CT scans allow for early detection and mitigation of issues, as well as prediction of any changes in dose distribution. While they state that the monitoring is non-invasive and does not hold any adverse effects to the patient, it could be argued that excessive CT tests may pose unnecessary radiation exposure to the patient, which would need to be further investigated.

As discussed above, there are many aspects of post-mastectomy reconstruction and radiation therapy treatments to temporary tissue expanders. Some issues deal with cosmesis and quality of life, while others deal with treatment plans and dosimetry, which directly affect locoregional recurrence and long-term survival of the patients. Breast cancer patients face the fight of their life when they are diagnosed, and whether they like it or not, many decisions must be made. The overall decision comes down to what is most important: cosmetic outcome or eradication of the cancer and long-term survival. Each patient must choose for herself, but it is pertinent that all possible routes of treatment and reconstruction as well as the benefits and risks are presented to the patient. With further research surrounding post-mastectomy reconstruction and the effect of

radiation therapy treatments on prostheses such as temporary tissue expanders, definitive answers can be given to help patients make decisions and provide what is most important: optimal patient care.



*Figure 3. An axial computed tomography slice showing radiation fields used to treat the chest wall after mastectomy (A) or mastectomy with immediate reconstruction using a tissue expander (B). The medial gray fields represent an anterior electron beam field that is geometrically matched to the white x-ray fields used to treat the lateral chest wall. The electron beam field has a rapid dose fall-off to minimize dose to the underlying lung. The gray arrows show the orientation of the radiation beams. The white arrows show the triangles of tissue in the medial chest wall that received less radiation dose at the junction of the fields. As shown, this triangle is much bigger when there is a tissue expander.*

## Works Cited

- Al-Ghazal, S. K., Blamey, R. W., & Fallowfield, L. (2000). Comparison of psychological aspects and patient satisfaction following breast conserving surgery, simple mastectomy and breast reconstruction. *European Journal of Cancer*, 36 (15) 1938-43.
- Al-Ghazal, S. K., Blamey, R. W., Fallowfield, L., & Sully, L. (2000). The psychological impact of immediate rather than delayed breast reconstruction. *European Journal of Surgical Oncology*, 26(1) 17-19.
- Andradas-Aragones, E., Blasco, J. A., Fernandez-Delgado, J., Lopez-Pedraza, M. J., Reza, M. M., Sanchez-Mendez, J. I., et al. (2008). Satisfaction with and psychological impact of immediate and deferred breast reconstruction. *Annals of Oncology*, 19(8)1430-1434.
- Arzu, I., Babiera, G., Buchholz, T. A., Hortobagyi, G. N., Hunt, K. K., Kronowitz, S. J., et al (2005). Immediate breast reconstruction can impact postmastectomy radiation. *American Journal of Clinical Oncology*, 28(5)485-494.
- Ashton, C., Goldson, A. L., Nibhanupudy, J. R., Shankar, R. A., & Sridhar, R. (2003). Immediate breast reconstruction: Impact on radiation management. *Journal of the National Medical Association*, 95(4)286-294.
- Babiera, G., Buchholz, T. A., Hunt, K. K., Kronowitz, S. J., Kuerer, H. M., McNeese, M. D., et al. (2004). Delayed-immediate breast reconstruction. *Plastic and Reconstructive Surgery*, 113(6)1617-1628.
- Ballangrud, A., Beal, K., Cordeiro, P. G., Damast, S., Disa, J. J., Hong, L., et al. (2006). Do metallic ports in tissue expanders affect postmastectomy radiation delivery? *International Journal of Radiation Oncology, Biology, and Physics*, 66(1)305-310.
- Benda, R. K., Feigenberg, S. J., Mendenhall, N. P., & Morris, C. G. (2003). Postmastectomy radiotherapy: Patterns of recurrence and long-term disease control using electrons. *International Journal of Radiation Oncology, Biology, and Physics*, 56(3)716-725.
- Bosworth, J. L., Derisi, D., Farber, L. A., Jhaveri, J. D., Kostroff, K., Maurer, V. E., et al. (2008). Clinical outcomes of postmastectomy radiation therapy after immediate breast reconstruction. *International Journal of Radiation Oncology, Biology, and Physics*, 72(3)859-865.
- Buchholz, T. A., McNeese, M. D., Perkins, G. H., & Strom, E. A. (2002). Controversies regarding the use of radiation after mastectomy in breast cancer. *The Oncologist*, 7(6)539-546.
- Buchholz, T. A., Butler, C. E., Ibrahim, N. K., Kronowitz, S. J., Langstein, H. N., Lee, G. K., et al. (2006). The impact of immediate breast reconstruction on the technical delivery of postmastectomy radiotherapy. *International Journal of Radiation Oncology, Biology, and Physics*, 66(1)76-82.
- Cederna, P., Fraass, B. A., Graves-Ditman, M., Griffith, K., Krueger, E. A., Moni, J., et al. (2004). Dosimetry around metallic ports in tissue expanders in patients receiving postmastectomy radiation therapy: An ex vivo evaluation. *Medical Oncology*, 29(1)49-54.

- Donegan, W. L. & Spratt, J. S. (2002). *Cancer of the breast: 5<sup>th</sup> edition*. St. Louis, MO: Saunders.
- Druss, R. G., Forde, K. A., Gump, F. E., Kister, S. J., McGrath, M. H., & Stevens, L. A. (1984). The psychological impact of immediate breast reconstruction for women with early breast cancer. *Plastic and Reconstructive Surgery*, 73(4)619-28.
- Hudis, C. A., Norton, L., & Winchester, D. J. (2006). *Breast cancer: 2<sup>nd</sup> edition*. Hamilton, Ontario: BC Decker.
- Kronowitz, S. J. & G. L. Robb. (2004). Breast reconstruction with postmastectomy radiation therapy: current issues. *Plastic and Reconstructive Surgery*, 114(4)950-960.
- Morgan, A. M. & Thompson, R. C. A. (2005). Investigation into dosimetric effect of a MAGNA-SITE™ tissue expander on post-mastectomy radiotherapy. *Medical Physics*, 32(6)1640-1646.
- Mosiello, G. & Shons, A. R. (2001). Postmastectomy breast reconstruction - Current techniques. *Cancer Control*, 8(5)419-426.

